

# Lead Availability in Slug-Shot White-tailed Deer

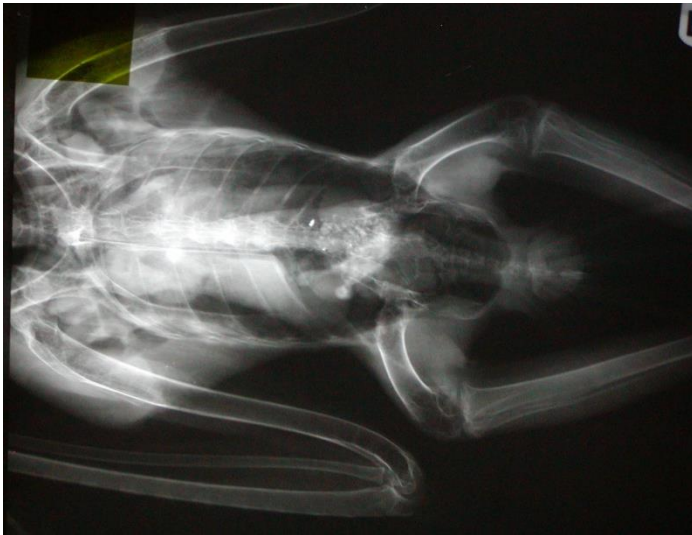## Preliminary Report 2009 ©

Kay Neumann, B.A., M.S., Executive Director  
SOAR – Saving Our Avian Resources  
<https://soarraptors.org>

### Introduction

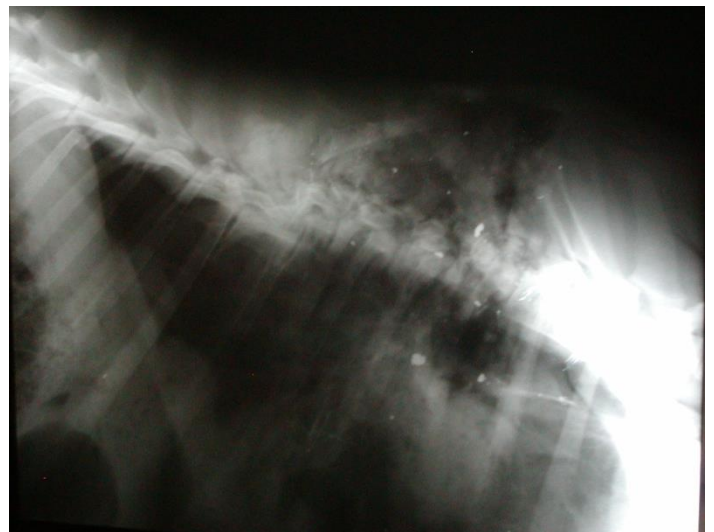
Iowa wildlife rehabilitators have been admitting an alarming number of bald eagles during their wintering season, sick and dying from lead poisoning. Many eagles admitted for trauma have also shown abnormal lead levels, suggesting the trauma was secondary to some impairment caused by the lead in their systems. The five-year data base (2004 – 2009) includes information on over 130 eagles. Sixty percent of the eagles admitted to rehabilitators have abnormal lead levels in blood, liver, or bone. This is a much higher percentage than the random types of injuries, seen in other species (Neumann 2009).

After gathering as much data as possible on this phenomenon, evidence points to lead fragments in deer carcasses shot with lead slugs as a source of the ingested lead.



*x-ray of deer carcass shot with two lead slugs showing lead fragments >>*

*<<full body x-ray of a bald eagle with lead shrapnel in digestive tract*



In recent years, Iowa hunters have harvested approximately 150,000 deer each year (IDNR 2008). Researchers estimate a ten percent wounding rate (i.e. a deer that is shot, but the hunter is unable to retrieve it) (Nixon 2001). There would be an ample availability of deer carcasses for scavengers after and during the shotgun deer seasons. Field observations of eagles confirm their behavior of seeking out and feeding from large carcasses for several days at a time.



<< bald eagle photographed with a trail cam feeding from a deer carcass

Clinical trials have documented that a very small amount of lead ingested by an eagle is lethal. Less than 200 mg of lead (a piece smaller than one piece of #4 shot) can cause death (Pattee et al 1981). It is not known, at this point, what effect lead poisoning and exposure could have on bald eagle populations. Certainly, not all injured or dead eagles are found and brought to rehabilitation facilities. Twenty-two eagles have died from lead poisoning or exposure thus far in 2009.

Does this translate into 100, 200, or more deaths in the field? Is this a sustainable mortality rate for eagles? Preventable poisoning should not be an acceptable form of mortality. With a large number of eagles now wintering in Iowa during the shotgun deer seasons, it would seem wise to try to eliminate this potential threat to a species only recently removed from the endangered species list.

There have been several studies done to document lead availability in rifle shot deer carcasses (Hunt et al 2006, MDNR 2008) and the resulting venison (Cornatzer et al 2009, Hunt et al 2009). Most lead rifle bullets are designed to fragment on impact and leave behind a large number of lead fragments that are impossible to remove completely from the processed meat. Lead slugs have a much different design.

## Methods

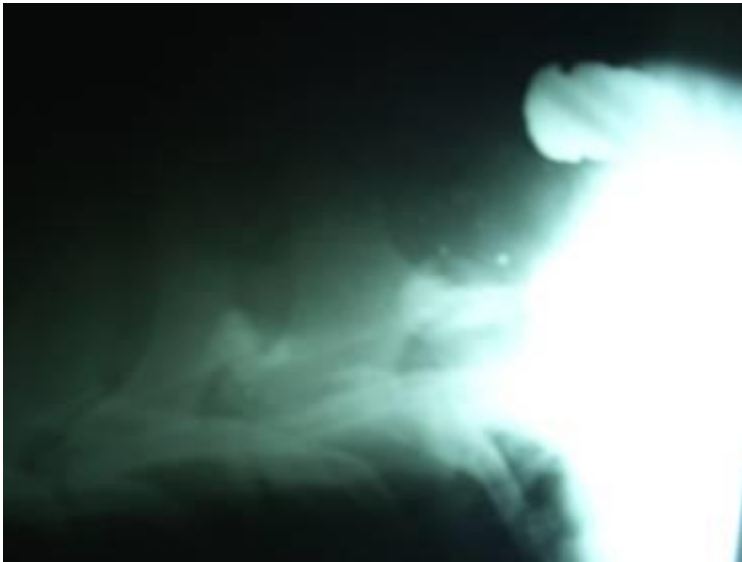To document the incidence, abundance, and distribution of available lead fragments in white-tailed deer carcasses harvested with lead slugs, SOAR partnered with Whiterock Conservancy to x-ray field-dressed deer carcasses and gut piles during the winter of 2008. Fourteen field dressed deer carcasses and the resulting gut piles were borrowed from cooperating hunters for x-ray. These deer were shot with lead slugs during the regular December shotgun deer seasons in Iowa. Five field dressed deer shot with solid copper deer slugs and the resulting gut piles were also x-rayed.



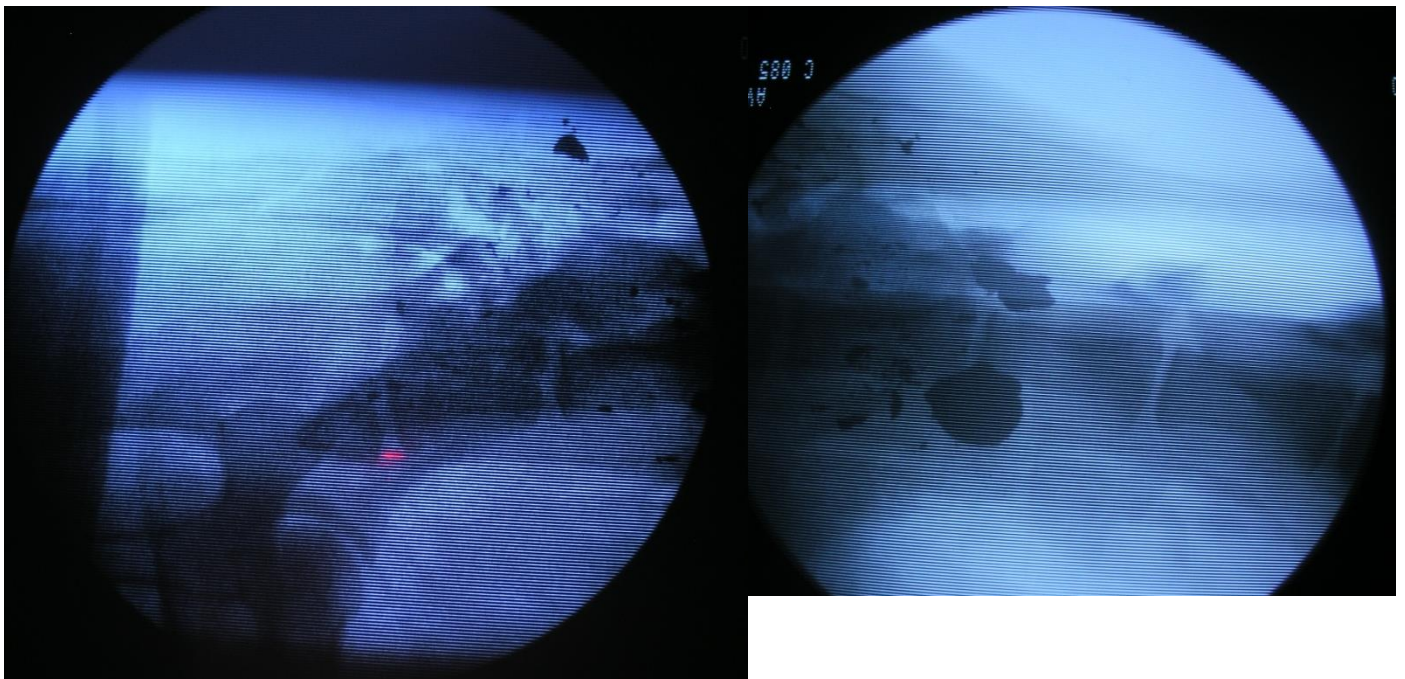
## Results

Twelve of the 14 slug shot deer carcasses contained lead fragments (85.7%). Three of the 12 with fragments also contained an entire slug. The slug did not pass through the animal, but remained lodged in or near the spine. Several of the deer had been shot more than once. Ten of the 14 gut piles contained lead fragments (71.4%).

None of the copper slug shot deer contained visible fragments of copper. One retained the entire copper slug intact in the flank. One gut pile contained an entire copper slug.



This x-ray shows most of lead slug remaining in a field dressed deer. The slug is lodged just above the spine, between the shoulder blades. There are also lead fragments in the back-strap meat.

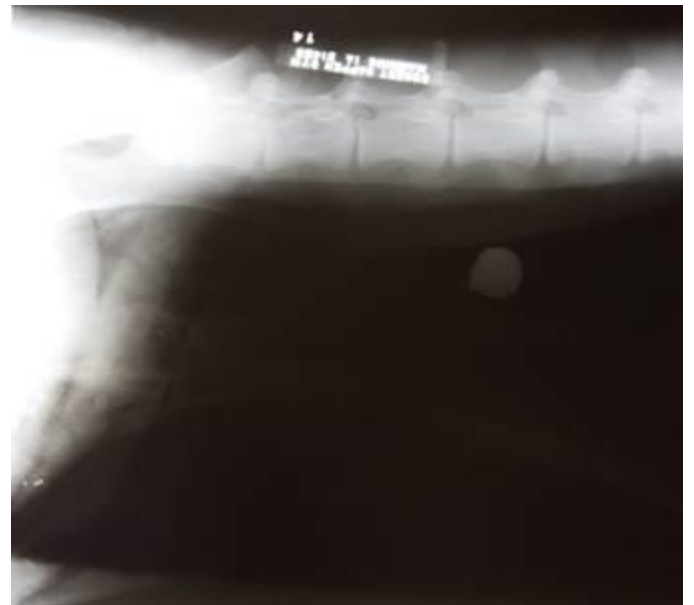
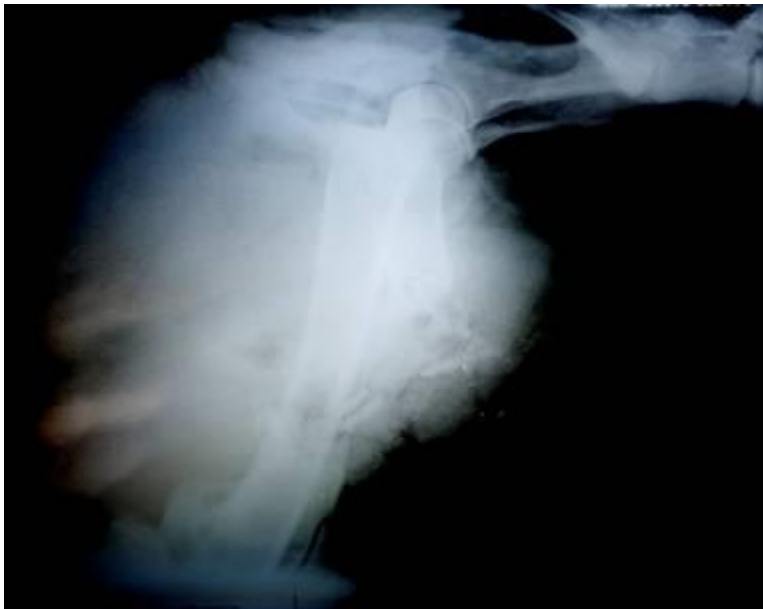

The above is a fluoroscope image of a deer shot with a lead slug, with the shooter aiming at the posterior of the deer. Lead on a fluoroscope image is black, the reverse of an x-ray where

lead appears brilliantly white. The slug fragmented on impact with the pelvic bones and traveled up the spine leaving many large fragments of lead.



This x-ray shows a deer that has been shot with a lead slug in the shoulder blade from the side. The slug fragmented on impact with the shoulder blade and scattered lead fragments throughout that area of the carcass.



The above series of x-rays show a lead slug traveling through one femur (large hind leg bone) fracturing it and leaving many small lead fragments in the “ham” of the animal. The slug continued on and remained lodged in the flank of the animal. This deer was also shot from behind.



On the left in this photo is a copper slug removed from the flank of a field dressed deer carcass. On the right is a lead slug removed from the flank of a field dressed deer carcass. The lead slug here is the round object shown in the x-ray above. The remainder of the slug is in the “ham” of the deer.



This x-ray shows large pieces of the lead slug fragmenting downward along the ribs from a spine shot.

### **Discussion**

From the x-ray evidence gathered, when lead slugs hit bones within a deer the slug fragments. These fragments can be as large as an entire slug and range downward in size to tiny, barely visible pieces. This work clearly shows that lead could be available to eagles scavenging from deer carcasses shot with lead slugs. It may also have implications for the people eating the venison made from deer shot with lead slugs.

According to the cooperating hunters, they were very pleased with the performance of the copper slugs. The hunters that help to manage the deer herd at Whiterock Conservancy were able to shoot 52 deer the opening weekend of the shotgun season in 2008 using only copper slugs. The resulting venison, should not contain lead and the deer management goals for the area were still accomplished.

## Resources

Cornatzer, W.E., E.F. Fogarty, and E.W. Cornatzer. 2009. Qualitative and quantitative detection of lead bullet fragments in random venison packages donated to the Community Action Food Centers of North Dakota, 2007. *In* R.T. Watson, M. Fuller, M. Pokras, and W.G. Hunt (eds.). *Ingestion of Lead From Spent Ammunition: Implications for Wildlife and Humans*. The Peregrine Fund, Boise, Idaho, USA. DOI 10.4080/ilsa.2009.0111

Harmata, A.R., and M. Restani. 1995. Environmental contaminants and cholinesterase in blood of vernal migrant bald and golden eagles in Montana. *Intermountain Journal of Sciences* 1:1-15.

Hunt, G. et al. 2006. Bullet Fragments in Deer Remains: Implications for Lead Exposure in Avian Scavengers. *Wildlife Society Bulletin* 34(1):167-170.

Hunt, W.G., Watson R.T., Oaks J.L., Parish C.N., Burnham K.K., et al. 2009. Lead Bullet Fragments in Venison from Rifle-Killed Deer: Potential for Human Dietary Exposure. *PLoS ONE* 4(4): e5330. doi:10.1371/journal.pone.0005330

Iowa Department of Natural Resources. Trends in Iowa Wildlife Populations and Harvest. Iowa Department of Natural Resources – Wildlife Bureau, Des Moines, IA

Minnesota Department of Natural Resources. 2008. Examining Variability Associated with Bullet Fragmentation and Deposition in White-tailed Deer and Domestic Sheep. Minnesota Department of Natural Resources, St. Paul, Minnesota, USA.

Neumann, K. 2009. Bald Eagle Lead Poisoning in Winter. *In* R.T. Watson, M. Fuller, M. Pokras, and W.G. Hunt (eds.). *Ingestion of Lead from Spent Ammunition: Implications for Wildlife and Humans*. The Peregrine Fund, Boise, Idaho, USA. DOI 10.4080/ilsa.2009.0119

Nixon, C.M., L.P. Hansen, P.A. Brewer, J.E. Chelsvig, T.L. Esker, D. Etter, J.B. Sullivan, R.G. Koerkenmeier, and P.C. Mankin. 2001. Survival of white-tailed deer in intensively farmed areas of Illinois. *Canadian Journal of Zoology* 79:581-588.

Pattee, O.H. et al. 1981. Experimental lead-shot poisoning in bald eagles. *Journal of Wildlife Management* 45:806-810.

Wayland, M. and T. Bollinger. 1999. Lead exposure and poisoning in bald eagle and golden eagles in the Canadian prairie provinces. *Environmental Pollution* 104:341-350.

## Acknowledgements

Whiterock Conservancy, Manning Veterinary Associates, AmeriCorps Volunteers, Colton Pulver, Jeanne Feasel, Darwin Pierce, Jason Schultes, Elizabeth Hill, Jon Judson, Liz Garst, Ed Golay, Dean Anderson, and Butch Goatser